



# Performance of Aspergillus PCR in cerebrospinal fluid for the diagnosis of cerebral aspergillosis

Sébastien Imbert, Jean-Yves Brossas, Martine Palous, Isabelle Joly, Isabelle Meyer, Arnaud Fekkar

## ► To cite this version:

Sébastien Imbert, Jean-Yves Brossas, Martine Palous, Isabelle Joly, Isabelle Meyer, et al.. Performance of Aspergillus PCR in cerebrospinal fluid for the diagnosis of cerebral aspergillosis. *Clinical Microbiology and Infection*, Wiley, 2017, <10.1016/j.cmi.2017.06.012>. <hal-01548945>

**HAL Id: hal-01548945**

**<http://hal.upmc.fr/hal-01548945>**

Submitted on 28 Jun 2017

**HAL** is a multi-disciplinary open access archive for the deposit and dissemination of scientific research documents, whether they are published or not. The documents may come from teaching and research institutions in France or abroad, or from public or private research centers.

L'archive ouverte pluridisciplinaire **HAL**, est destinée au dépôt et à la diffusion de documents scientifiques de niveau recherche, publiés ou non, émanant des établissements d'enseignement et de recherche français ou étrangers, des laboratoires publics ou privés.

**Performance of *Aspergillus* PCR in cerebrospinal fluid for the diagnosis of cerebral aspergillosis**

**Sébastien Imbert<sup>1</sup>, Jean-Yves Brossas<sup>1,2</sup>, Martine Palous<sup>1</sup>, Isabelle Joly<sup>1</sup>, Isabelle Meyer<sup>1</sup>, Arnaud Fekkar<sup>1,2,3</sup> #**

<sup>1</sup> AP-HP, Groupe hospitalier Pitié-Salpêtrière, Service de Parasitologie Mycologie, F-75013, Paris, France

<sup>2</sup> Centre d'Immunologie et des Maladies Infectieuses, CIMI-Paris, F-75013, Paris, France

<sup>3</sup> Sorbonne Universités, UPMC Univ Paris 06, F-75005, Paris, France

# Corresponding author

**Running title:** *Aspergillus* PCR in cerebrospinal fluid

**Corresponding author:**

A. Fekkar, Service de Parasitologie-Mycologie, Pavillon Laveran, Hôpital de La Pitié-Salpêtrière, Boulevard de l'Hôpital, 75013 Paris, France

E-mail: [arnaud.fekkar@aphp.fr](mailto:arnaud.fekkar@aphp.fr)

Tel: +33 1 42 16 01 84      Fax: +33 1 42 16 01 15

**Keywords:**

*Aspergillus fumigatus*, *Aspergillus* PCR, Cerebrospinal Fluid, Fungal Infection, Solid Organ Transplant, Haematology, Galactomannan

## **ABSTRACT.**

**Objectives:** cerebral aspergillosis is a rare but often fatal form of invasive aspergillosis that remains difficult to diagnose. The literature has shown the value of *Aspergillus* PCR in blood-derived samples for the diagnosis of invasive aspergillosis but provides far less information for cerebrospinal fluid (CSF) in cerebral aspergillosis. Here, we evaluated the usefulness of an *Aspergillus* PCR assay performed on CSF for the diagnosis of cerebral aspergillosis.

**Methods:** this retrospective study involved 72 patients with suspected cerebral aspergillosis for a total of 88 CSF samples in whom CSF *Aspergillus* PCR was performed.

**Results:** seventeen patients had proven/probable invasive aspergillosis according to the European Organisation for Research and Treatment of Cancer/Mycoses Study Group (EORTC/MSG) criteria, including twelve cases of proven/probable cerebral aspergillosis. *Aspergillus* PCR in CSF was positive in nine of the twelve patients with cerebral aspergillosis, i.e. 75% sensitivity. In contrast, CSF culture was positive for *Aspergillus* in only two patients. In the non cerebral aspergillosis group (60 patients), PCR was positive in one patient, i.e., 98.3% specificity. In this particular population of high-risk patients with suspicion of cerebral aspergillosis, the disease incidence was 16.7%. Therefore, the positive and negative predictive values of PCR were 90% and 95.2% respectively.

**Conclusion:** the results of this study indicate that *Aspergillus* PCR in CSF is an interesting tool that may eliminate the need for cerebral biopsy in patients with suspected cerebral aspergillosis.

## **INTRODUCTION.**

Cerebral aspergillosis (CA) is a rare clinical form of invasive aspergillosis with a mortality rate of up to 90% [1], whose diagnosis remains challenging to this day [2, 3]. Indeed, the diagnostic gold standard relies on histopathological examination of brain tissue biopsies

which are rarely performed. Imaging studies, especially magnetic resonance imaging (MRI), can be helpful. Cerebral abscesses and aneurysms are the main characteristics found during CA but these findings are not specific and depend on the mode of dissemination of the infection [4]. Cerebrospinal fluid (CSF) stands as an alternative. It can be subjected to the same tests used in blood-derived samples or in bronchoalveolar lavage samples (BAL) to diagnose invasive aspergillosis, such as culturing, galactomannan determination or PCR. Several studies have shown the utility of galactomannan determination in CSF for the diagnosis of CA, but few were focused on the performance of *Aspergillus* PCR despite its demonstrated value for the diagnosis of invasive aspergillosis when performed on blood-derived samples [5, 6]. In the few studies that have looked at *Aspergillus* PCR in CSF, the technique yielded excellent sensitivity and specificity, up to 100% and 93% respectively, but those data need confirmation due to the small number of patients included in the studies [7, 8]. Thus, for the present study, we sought to enlarge this knowledge base by evaluating the performance of an in-house *A. fumigatus* real-time PCR using CSF from patients with suspected cerebral aspergillosis.

## **MATERIALS AND METHODS.**

This retrospective single-centre analysis was performed between February 2012 and January 2016 in La Pitié Salpêtrière hospital, a tertiary care centre in Paris, France. As the study was performed using results get from routine clinical practice, any authorization from a research ethics committee was not required. Patients in whom a CSF *Aspergillus* PCR was prescribed by clinicians were considered to have a suspected CA and were included in the study. If clinical or radiological data were lacking we thereafter excluded these patients from analyses. CA was defined as proven when patients had a positive *Aspergillus* culture in CSF or brain biopsy tissue. It was defined as probable when patients had cerebral radiological findings

suggestive of the diagnosis (e.g. cerebral abscess, meningeal enhancement or vasculitis) and a proven or probable invasive aspergillosis elsewhere, as previously reported [9]. Patients were diagnosed as no CA when they had no invasive aspergillosis, or had invasive aspergillosis with cerebral abnormalities due to another aetiology.

We used a real-time PCR that targets a previously-described 67-bp segment of a 28S ribosomal RNA coding DNA [5, 10]. Extraction, amplification and quantification were performed as previously described [11], excepted if CSF volume was below 1 mL. In that case, the totality of the CSF sample was centrifuged and DNA extraction was performed on 200 µL of the centrifugation pellet, using the extractions columns of the QIAamp DNA Blood Mini Kit (Qiagen).

## **RESULTS.**

Over the study period, PCR was performed in 86 patients and clinical and radiological data were available for 72 patients (88 CSF samples). Diagnosis of proven or probable CA was made for five and seven patients, respectively. Among them, 8 patients suffered from CA with additional organ involvement and four had only an isolated CA. Finally, 5 patients suffered from proven/probable invasive aspergillosis but without CA (Figure 1). Incidence of CA in this at-risk population was 16.7% (12/72).

Clinical and radiological findings of patients suffering from CA are shown in Table S1.

CSF *Aspergillus* PCR was positive in nine of the 12 patients with CA, leading to a sensitivity of 75% (95% confidence interval [CI], 62.5-87.5%) (Table 1). Mycological cultures of CSF were positive in only two cases, (sensitivity of 16.7% [95 CI, 0-37.8%]), all for *A. fumigatus*. Four biopsy specimens were also positive for *A. fumigatus*, thus establishing a proven diagnosis. CSF PCR was positive for three of these four biopsy-proven cases and negative for

one (this latter having also a negative galactomannan index and a negative mycological culture of CSF).

Of the 60 patients without CA, only one had a positive PCR in CSF and all CSF cultures were negative. Considering these results, the specificity, the positive predictive value and the negative predictive value of the *A. fumigatus* PCR in CSF were 98.3% (95% CI, 95.5-100%), 90% (95% CI, 71.5-100%) and 95.2% (95% CI, 89.9-100%) respectively.

Positive and negative likelihood ratio were 45 (95% CI, 6.27-323) and 0.254 (95% CI, 0.10-0.68) respectively, and diagnosis odds ratio was 177 (95% CI, 16-1892).

## **DISCUSSION.**

In this study we found that *Aspergillus* PCR in CSF is a useful tool for the diagnosis of CA. In this setting, it provided 75% sensitivity, a rate comparable with its performance in blood-derived samples [5, 6]. Specificity, PPV and NPV were very good in our study, respectively 98.3%, 90% and 95.2%.

CA is a rare but severe infection associated with a high mortality rate [1]. Early initiation of antifungal therapy may improve the prognosis, but this is hampered by the diagnosis, which remains a challenge in current practice. Therefore, mycological tools have been proposed for use in CSF. Galactomannan index determination and mycological culture of CSF have been recognised within the EORTC/MSG criteria for the diagnosis of CA [12]. *Aspergillus* PCR, although it has shown its value for the diagnosis of invasive aspergillosis in blood-derived samples, has not yet been included in the EORTC/MSG criteria and expert recommendations for its use carry precautions [13]. In our study, CSF PCR greatly outperformed mycological culture, the latter being positive in only two patients (16.7%). Direct evidence of fungal elements in CSF using a silver staining approach was not observed. Although mycological examination of cerebral biopsy tissue was very useful, it was available for only four patients.

However, among those four patients, three had positive CSF PCRs, suggesting that PCR could be used as a substitute for particularly invasive and sometimes unattainable brain biopsies. Unfortunately, we were not able to fully compare the performances of PCR to that of the galactomannan index determination because it was determined in only 5 patients.

Because of the small number of cerebral aspergillosis cases, few studies have evaluated the performances of *Aspergillus* PCR in CSF. Although in this study cases were also limited, we nonetheless report one of the largest series of cerebral aspergillosis cases, and to our knowledge, the largest series with PCR results. Reinwald *et al* previously reported a sensitivity of 100% for PCR in CSF [8]. However, their study comprised only eight cases and employed a nested PCR that can lead to more false-positive results (specificity was 93% in their study) [14]. In our study, the 3 CSF PCR negative results, leading to a comparatively lower sensitivity, may be explained in part by one case of probable CA due to *A. niger*, a species not recognised by our PCR. The 2 other negative PCR results were found in 2 patients suffering from only cerebral abscesses without associated meningitis (0 and 1 white blood cell in CSF), that can also explain a negative result in CSF.

In conclusion, the results of this study indicate that performing *Aspergillus* PCR in CSF is an interesting tool for the diagnosis of cerebral aspergillosis and potentially a substitute for invasive cerebral abscess punctures. However, prospective multicentre studies are needed to confirm these results in the largest possible population, and to compare the performance of PCR with that of the galactomannan index when performed on CSF.

**TRANSPARENCY DECLARATION.** The authors declare no conflicts of interest.

**FUNDING.** This work was supported by internal funding.

## FIGURE CAPTION

**Figure 1:** flow chart illustrating the number of patients and samples included in the study.

CSF: cerebrospinal fluid; IA: invasive aspergillosis; CA: cerebral aspergillosis

## REFERENCES.

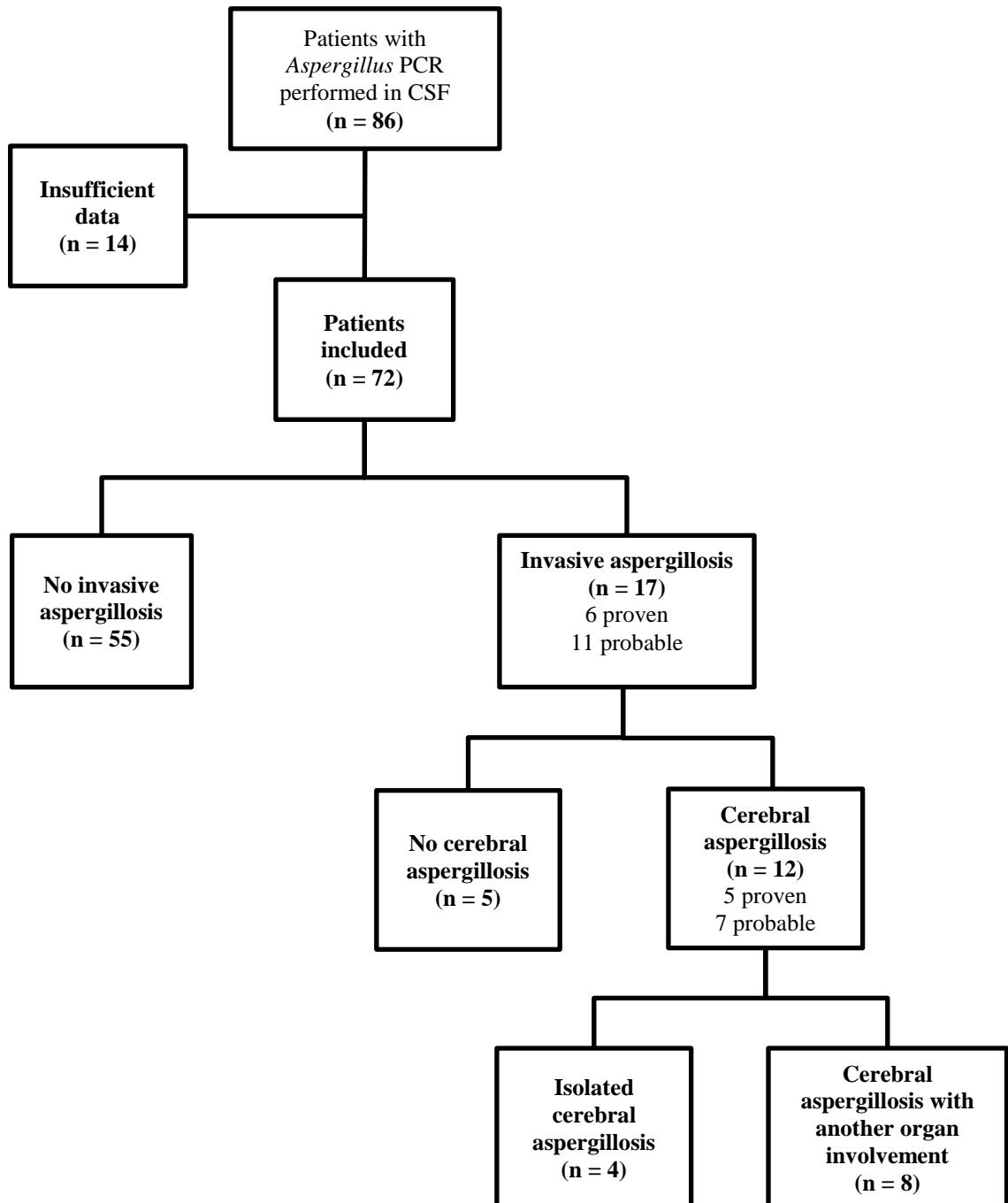
- 1 Lin SJ, Schranz J, Teutsch SM. Aspergillosis case-fatality rate: Systematic review of the literature. *Clin Infect Dis.* 2001; **32**: 358-366.
- 2 Kourkoumpetis TK, Desalermos A, Muhammed M, Mylonakis E. Central nervous system aspergillosis: A series of 14 cases from a general hospital and review of 123 cases from the literature. *Medicine (Baltimore).* 2012; **91**: 328-336.
- 3 Spapen H, Spapen J, Taccone FS, et al. Cerebral aspergillosis in adult critically ill patients: A descriptive report of 10 patients from the asp ICU cohort. *Int J Antimicrob Agents.* 2014; **43**: 165-169.
- 4 Marzolf G, Sabou M, Lannes B, et al. Magnetic resonance imaging of cerebral aspergillosis: Imaging and pathological correlations. *PLoS One.* 2016; **11**: e0152475.
- 5 Imbert S, Gauthier L, Joly I, et al. *Aspergillus* PCR in serum for the diagnosis, follow-up and prognosis of invasive aspergillosis in neutropenic and non-neutropenic patients. *Clin Microbiol Infect.* 2016.
- 6 Arvanitis M, Ziakas PD, Zacharioudakis IM, Zervou FN, Caliendo AM, Mylonakis E. PCR in diagnosis of invasive aspergillosis: A meta-analysis of diagnostic performance. *J Clin Microbiol.* 2014; **52**: 3731-3742.



- 7 Hummel M, Spiess B, Kentouche K, et al. Detection of aspergillus DNA in cerebrospinal fluid from patients with cerebral aspergillosis by a nested PCR assay. *J Clin Microbiol.* 2006; **44**: 3989-3993.
- 8 Reinwald M, Buchheidt D, Hummel M, et al. Diagnostic performance of an aspergillus-specific nested pcr assay in cerebrospinal fluid samples of immunocompromised patients for detection of central nervous system aspergillosis. *PLoS One.* 2013; **8**: e56706.
- 9 Chong GM, Maertens JA, Lagrou K, Driessen GJ, Cornelissen JJ, Rijnders BJ. Diagnostic performance of galactomannan antigen testing in cerebrospinal fluid. *J Clin Microbiol.* 2016; **54**: 428-431.
- 10 Challier S, Boyer S, Abachin E, Berche P. Development of a serum-based taqman real-time PCR assay for diagnosis of invasive aspergillosis. *J Clin Microbiol.* 2004; **42**: 844-846.
- 11 Imbert S, Gauthier L, Joly I, et al. *Aspergillus* PCR in serum for the diagnosis, follow-up and prognosis of invasive aspergillosis in neutropenic and nonneutropenic patients. *Clin Microbiol Infect.* 2016; **22**: 562 e561-568.
- 12 De Pauw B, Walsh TJ, Donnelly JP, et al. Revised definitions of invasive fungal disease from the european organization for research and treatment of cancer/invasive fungal infections cooperative group and the national institute of allergy and infectious diseases mycoses study group (EORTC/MSG) consensus group. *Clin Infect Dis.* 2008; **46**: 1813-1821.
- 13 Patterson TF, Thompson GR, 3rd, Denning DW, et al. Practice guidelines for the diagnosis and management of aspergillosis: 2016 update by the infectious diseases society of america. *Clin Infect Dis.* 2016; **63**: e1-e60.

- 14 White PL, Bretagne S, Klingspor L, et al. *Aspergillus* PCR: One step closer to standardization. *J Clin Microbiol.* 2010; **48**: 1231-1240.

Figure 1



Patient	Age	Sex	CA	Primary site	Underlying disease Risk factor	Corticosteroid dose >0,3 mg/kg/day	Clinical symptoms at sampling date	Radiological findings (MRI)	Antifungal therapy prior to sample	Antifungal treatment after diagnosis	3-months outcome
1	50	F	Probable	Pulmonary	AML, allogeneic HSCT	No	Unilateral mydriasis and exophthalmia, then impaired consciousness	Ischemia and vasculitis	No	Voriconazole and L-AmB	Death
2	61	M	Probable	Pulmonary	AML, allogeneic HSCT	Yes	Confusion	Hypodense lesion	No	Voriconazole	Death
3	62	M	Proven	Cerebral	AML, allogeneic HSCT	No	Cerebellar syndrome	Hypodense lesion	Posaconazole	Voriconazole and L-AmB	Survival
4	40	M	Probable	Pulmonary	AML, allogeneic HSCT	Yes	Febrile confusion, coma and generalized epilepsy	Multiple abscesses	L-AmB	Voriconazole	Death
5	78	F	Proven	Cerebral	Lymphoma treated by methotrexate-based therapy Cerebral biopsy 3 months before	No	Febrile headache	Parietal and frontal abscesses	No	Voriconazole	Death
6	68	M	Proven	Cerebral	Kidney transplant - Nasopharynx biopsy 1 month before	No	Binocular diplopia	Osteitis, abscess and ischemia	No	Voriconazole	Survival
7	68	M	Proven	Internal ear	Kidney transplant - Internal ear surgery 3 months before	Yes	Meningeal syndrome then confusion	Petrous osteitis and temporal abscesses	No	Voriconazole	Survival
8	55	M	Probable	Pulmonary	Liver transplant	Yes	Headache and low back pain	Frontal abscess, subarachnoid haemorrhage and ischemia	No	Voriconazole and caspofungin	Survival
9	58	F	Probable	Sinus	Metastatic solid organ malignancy	No	Hemiplegia	Ischemia, meningitis and vasculitis	No	Voriconazole	Survival
10	71	F	Probable	Pulmonary	Ethylc cirrhosis (Child-Pugh 10) and acute alcoholic hepatitis	Yes	Impaired consciousness	Haemorrhage and nodule	Voriconazole	Voriconazole	Death
11	57	M	Probable	Pulmonary	ICU ARDS + ECMO	No	Not determinable (intubated/ventilated)	Occipital abscess	Voriconazole	Voriconazole and L-AmB	Survival
12	77	F	Proven	Cerebral	No evident host factors Nasopharynx biopsy 2 months before	No	Headache then impaired consciousness	Skull osteomyelitis, ischemia and vasculitis	No	Voriconazole	Death

**Table 1:** clinical and radiological characteristics of 12 patients suffering from cerebral aspergillosis. CA: cerebral aspergillosis, ECMO: extra corporal membrane oxygenation, ARDS: acute respiratory distress syndrome, AML: acute myeloid leukemia, HSCT: hematopoietic stem cell transplant, L-AmB: liposomal amphotericin B, MRI: magnetic resonance imaging

		No IA	Invasive aspergillosis	
			No CA	CA
Patients (n)		55	5	12
Median age (years)		51	45	61.5
Sexe ratio (male/female)		39/16	3/2	7/5
Underlying disease ; n (%)	Hematological malignancy	4 (7.3)	0	2 (16.6)
	HSCT recipients	10 (18.2)	3 (60)	3 (25)
	SOT recipients	8 (14.5)	1 (20)	3 (25)
	Solid organ malignancy	5 (9.1)	0	1 (8.3)
	HIV infected	9 (16.4)	0	0
	Other	12 (21.8)	1 (20)	2 (16.6)
	No found	7 (12.7)	0	1 (8.3)
Final diagnosis ; n (%)	Cerebral aspergillosis	NA	NA	12 (100)
	Other infectious etiology	18 (32.7)	0	NA
	Malignancy	13 (23.6)	1 (20)	NA
	Neurological disease	11 (20)	1 (20)	NA
	Neurological toxicity	7 (12.7)	3 (60)	NA
	Unknown	6 (10.9)	0	NA
3-months mortality (%)		12 (21.8)	2 (40)	6 (50)

**Table S1:** Characteristics of patients for whom an *A. fumigatus* PCR assay in cerebro-spinal fluid was performed.

IA: invasive aspergillosis, CA: cerebral aspergillosis, HSCT: hematopoietic stem cell transplant, SOT: solid organ transplant; NA: not applicable